

Parathyroid cysts: the Latin-American experience

Alejandro Román-González^{1,2}, Natalia Aristizábal³, Carolina Aguilar², Karen Palacios⁴, Juan Camilo Pérez^{4,5}, Alejandro Vélez-Hoyos^{4,5}, Carlos Simon Duque⁶, Alvaro Sanabria⁷

¹Department of Endocrinology, Hospital Universitario San Vicente Fundación, Medellín, Colombia; ²Department of Endocrinology, Universidad de Antioquia, Medellín, Colombia; ³Department of Endocrinology, Universidad Pontificia Bolivariana, Medellín, Colombia; ⁴Department of Pathology, Hospital Pablo Tobón Uribe, Medellín, Colombia; ⁵Department of Pathology, Dinámica IPS, Medellín, Colombia; ⁶Department of Surgery, Hospital Pablo Tobón Uribe, Medellín, Colombia; ⁷Department of Surgery, Universidad de Antioquia, Medellín, Colombia

Contributions: (I) Conception and design: A Román-González, NA Henao, C Aguilar, K Palacios, A Vélez-Hoyos; (II) Administrative support: A Román-González, A Vélez-Hoyos; (III) Provision of study materials or patients: JC Pérez, A Vélez-Hoyos, CS Duque, A Sanabria; (IV) Collection and assembly of data: A Román-González, NA Henao, C Aguilar, K Palacios, JC Pérez, A Vélez-Hoyos; (V) Data analysis and interpretation: All authors; (VI) Manuscript writing: All authors; (VII) Final approval of manuscript: All authors.

Correspondence to: Dr. Alejandro Román-González. Oficina Endocrinología y Diabetes, Hospital Universitario San Vicente Fundación, Carrera 93 No. 50^a-91, Medellín, Colombia. Email: alejoroman@gmail.com.

Background: Parathyroid cyst is an infrequent and unsuspected disease. There are more than 300 hundred cases reported in the world literature, a few of them are from Latin America. The experience of our centers and a review of the cases are presented.

Methods: Case report of a series of patients with parathyroid cyst from our institutions according to the CARE guidelines (Case Reports). A search of Medline, Embase, BIREME (*Biblioteca Regional de Medicina*) LILACS (*Literatura Latinoamericana y del Caribe en Ciencias de la Salud*), Google Scholar and Scielo (*Scientific Electronic Library on Line*) databases and telephonic or email communications with other experts from Latin-America was performed.

Results: Six patients with parathyroid cyst were found in our centers in Colombia. Most of them were managed with aspiration of the cyst. Two of them required surgery. Only one case was functional. Twelve reports from Latin America were found for a total of 18 cases in our region adding ours.

Conclusions: Parathyroid cysts are uncommonly reported in Latin America. Most of them are diagnosed postoperatively. Suspicion for parathyroid cyst should be raised when a crystal clear fluid is aspirated from a cyst. The confirmation of the diagnosis may be easily done if parathyroid hormone (PTH) level is measured in the cyst fluid.

Keywords: Parathyroid diseases; cyst; parathyroid hormone; ultrasonography; parathyroid gland

Submitted Nov 24, 2016. Accepted for publication Dec 06, 2016.

doi: 10.21037/gs.2016.12.08

View this article at: <http://dx.doi.org/10.21037/gs.2016.12.08>

Introduction

Parathyroid cysts are a rare entity. Clinically, they may present as asymptomatic nodules and sometimes may be confused with “thyroid nodules”. Parathyroid cysts must be always considered in the differential diagnosis of anterior neck masses (1). Most of them are non-functional, however 10–15% may secrete parathyroid hormone (PTH) (1,2)

and demonstrate the clinical manifestations of a primary hyperparathyroidism. Sometimes, parathyroid cysts may resemble giant goiters with extension to the mediastinum compressing the trachea causing obstructive symptoms (2). Treatment options include aspiration, percutaneous sclerosing agents injections or surgical resection (1,3). There are few reports of this disease from Latin America. The cases from Colombia with a review of the cases from

Table 1 Clinical characteristics of 18 patients with parathyroid cysts reported in Latin America

Country/author (reference)	Number of cases/sex	Age range (years)	Size range in cm	Functional/PTH level pg/mL from mass	Obstructive symptoms	Treatment
Colombia Current article	6/5 F; 1 M	24–56	2.2–10	1 functional/PTH in 4 cases: 300, 120, 44, 61	1; 5 no	Aspiration 4; surgery 2
Chile Mosso (5) Pérez (6)	4/3 F; 1 M	11–48	2–5.7	1 functional/PTH 1 case 5,800	1; 3 no	Surgery 4; one case prior aspiration that failed
Brazil Nardi (7) da Silva (8) Piccinato (9) Araujo Filho (10)	4/ 3 M; 1 F	25–49	3.5–8.9	No functional/1 PTH >2,500	2; 2 no	4 surgery one failed aspiration
Argentina Bürgesser (11)	2 F	61–84	8.5–8.9	2 functional	1 blood 230 pg/mL	2 surgery
Venezuela Vasallo (12)	1 F	52	1.4×0.3	No	No	Surgery
Cuba Fuentes Valdés (13)	1 M	32	8	Yes	Blood 133.8 pg/mL	Surgery

*, PTH measured in pg/mL (normal reference for blood 15–65 pg/mL).

Latin America are presented.

Methods

The experience of our centers in the diagnosis and management of parathyroid cyst is presented according to the CARE guidelines for reporting case reports (4), as well as a review of the topic and the cases reported from Latin America based on a search of Medline, Embase, BIREME, LILACS and Scielo databases with the Mesh terms “parathyroid diseases” and “cysts”. Also a search in Google Scholar was performed as well as a review of the references of all original articles and telephonic or email communications with other experts in the field from Latin America. The search was performed in English, Spanish and Portuguese. We found 654 references in Medline, 5 references were found in Scielo, 38 in Google Scholar, 54 in BIREME and 6 in LILACS. Publications of countries outside Latin America were excluded as well as reports about other types of cyst and narrative reviews. The study

was approved by ethics committee/ethics board of the Dinámica IPS.

Results

Case presentations from Colombia

During a nine year 9 years period [2005–2014], seven patients with parathyroid cyst were diagnosed and treated. One of the cases is excluded from this report due to incomplete clinical data. The demographic characteristics are presented in *Table 1*. The first two cases are presented as an example.

Case 1

Our first patient was a 44-year-old male with past medical history of paranoid schizophrenia and primary hypothyroidism who presents with an anterior neck mass of 1 year of evolution. Computed tomography showed a cystic mass of 10 cm largest diameter, in close contact with left thyroid lobule, extension to superior mediastinum

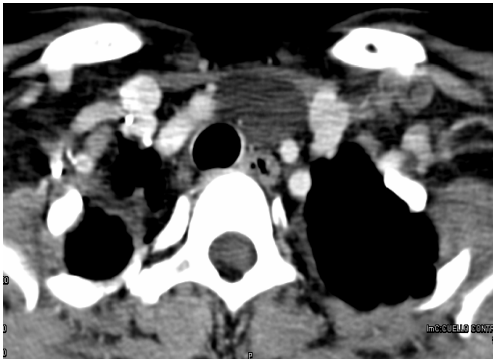


Figure 1 Contrast CT imaging of case 1.

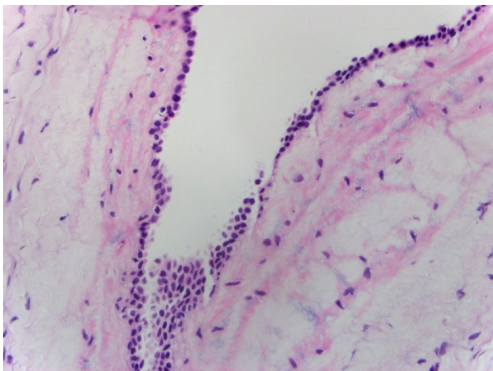


Figure 2 Micrograph of case 1. On hematoxylin eosin examination, a benign cystic lesion was observed with presence of cuboid epithelial cells and small columnar cell covered with fibrous tissue and parathyroid tissue in the wall of the cyst (40 \times).




Figure 3 Macroscopic aspect of the fluid of a parathyroid cyst. Clear fluid from parathyroid cyst aspiration with high PTH level (300 pg/mL). PTH, parathyroid hormone.

and displacement of common carotid artery and trachea (*Figure 1*). The patient underwent surgical resection and a parathyroid cyst was confirmed. On hematoxylin-eosin examination, a benign cystic lesion was observed with presence of cuboid epithelial cells and small columnar cell covered with fibrous tissue and parathyroid tissue in the wall of the cyst (*Figure 2*).

A cystic lesion is shown in close contact with left thyroid lobules and displacement of common carotid artery and the trachea.

Case 2

The second case was a healthy 25-year-old woman who presents with a 15-month history of a left paratracheal mass. The ultrasonography examination showed a simple cystic lesion in the left thyroid lobule. A fine needle aspiration was performed with the finding of clear fluid with high PTH levels (300 pg/mL) (*Figure 3*).

Cases from Latin America

The search of the literature retrieved 11 references of reported cases from countries of Latin America. The cases found with the relevant findings are presented in *Table 1* divided by country of origin of the report.

Discussion

Parathyroid cysts are an uncommon entity in the usual clinical setting (1,14,15). The first description of a parathyroid cyst and parathyroid gland in humans was done in 1880 by the Swedish anatomist Ivar Sandström (16-18), but only in 1905 the first surgical resection was performed by Goris (19) and several years later, Crile in 1953 become the first to diagnose a parathyroid cyst by fine needle aspiration (20). More than 300 hundred cases have been reported since those early studies (3). Parathyroid can be as high as 1.3% to 3% in patients undergoing parathyroidectomy for primary hyperparathyroidism (2,21,22) or as low as 0.075% in unselected patients by ultrasonography (23). There is an increased frequency in older individuals and is more common between fourth and fifth decade (24), however, there are several case reports in children (5,22,25). They are usually found in women, but functional cyst is more frequently found in men (15).

The localization is variable between mandible and the mediastinum (3,22). Although parathyroid cysts are usually non-functioning, around 10% may secrete PTH (2) and produce a primary hyperparathyroidism (26-28). This duality suggests differences in the pathogenesis of both types of cysts.

The clinical presentation is highly variable. It can be asymptomatic, present with obstructive symptoms or produce hypercalcemia with its known clinical symptoms. A familial form has been described, familial cystic parathyroid adenomatosis, in which cystic parathyroid adenomas are present in association with maxillary or mandible tumors similar to ossifying fibromas (29). In presence of a cystic mass in the neck in or around the thyroid, a crystal clear fluid in the aspirate should raise suspicion of a parathyroid cyst. A high PTH level in the fluid confirms the diagnosis of parathyroid cyst (30,31). A biochemical evaluation should be completed with parathyroid hormone and calcium in blood to rule out a functional parathyroid cyst. The differential diagnosis is always a cystic nodule of the thyroid.

The treatment of choice is percutaneous aspiration (32,33). Surgical resection should be performed when the parathyroid cyst is functional, in recurrent cases or when obstructive symptoms are present. Other therapeutic options include percutaneous sclerosing agent infusion such as ethanol or tetracycline (34-36). Aspiration has been the main treatment modality in our cases. Two of the cases from Colombia were previously reported (37,38) and during the last 10 years the clinical data of parathyroid cysts in our institutions has been compiled. Currently six cases have been diagnosed and managed and one case with no clinical data was seen from other city, but we believe that there are more cases as this entity is misdiagnosed or the treating physician or the pathologist is not aware of the existence of this disease. A similar situation may be occurring in other countries from Latin America as we only found 11 case reports and not a single review or original article. Most of them were cysts larger than 2 cm and very few had a determination of PTH level in the cyst fluid. Although some of them had obstructive symptoms and a large size, the uncertain diagnosis may be an explanation for the surgical management in almost all cases. This suggest that aspiration of any cyst and PTH measurement in those with a clear crystal fluid may improve the preoperative diagnosis and prevent a surgical procedure.

Our study might have not included some cases from our region that may have been missed from our search, as some journals were discontinued, not registered in databases

or do not have website or even also by the time the case was reported some new laboratory techniques were not available in Latin-American. This was prevented by a wide search in three languages, a search in Google Scholar and written communication with other colleagues. There is a need for more studies about parathyroid cyst in our region as well as a dedicated registry of this disease. In conclusion, we strongly suggest a PTH determination in a cyst fluid if it is highly characteristic (clear or crystal color) of parathyroid cyst.

Acknowledgements

To the office of Suministro de Documentos de la Biblioteca Médica de la Facultad de Medicina de la Universidad de Antioquia for providing manuscripts of the offline references.

Footnote

Conflicts of Interest: This work was presented partially as an Endocrine Society's Presidential Poster Competition for first authors during the Annual Meeting & Expo ENDO 2015. San Diego, California. Parathyroid cyst. The Latin America Experience.

Ethical Statement: The study was approved by institutional/regional/national ethics committee/ethics board of Dinámica IPS and written informed consent was obtained from all patients.

References

1. Wani S, Hao Z. Atypical cystic adenoma of the parathyroid gland: case report and review of literature. *Endocr Pract* 2005;11:389-93.
2. Ippolito G, Palazzo FF, Sebag F, et al. A single-institution 25-year review of true parathyroid cysts. *Langenbecks Arch Surg* 2006;391:13-8.
3. Pontikides N, Karras S, Kaprara A, et al. Diagnostic and therapeutic review of cystic parathyroid lesions. *Hormones (Athens)* 2012;11:410-8.
4. Gagnier JJ, Kienle G, Altman DG, et al. The CARE guidelines: consensus-based clinical case report guideline development. *J Clin Epidemiol* 2014;67:46-51.
5. Mosso L, López JM, Trincado P, et al. Functioning and non-functioning parathyroid cysts: entities with different origin and clinical characteristics in 2 cases. *Rev Med Chil*

- 1997;125:1049-54.
6. Pérez JA, Poblete MT, Salem C. Symptomatic parathyroid cysts. Report of one case. *Rev Med Chil* 2003;131:432-5.
 7. Nardi CE, Silva RA, Serafim CM, et al. Nonfunctional parathyroid cyst: case report. *Sao Paulo Med J* 2009;127:382-4.
 8. da Silva D, Machado M, Brito L, et al. Parathyroid cysts: diagnosis and treatment. *Revista Brasileira de Otorrinolaringologia* 2004;70:840-4.
 9. Piccinato CE, Cherri J, Llorach-Velludo MA, et al. Nonfunctioning parathyroid cyst simulating thyroid nodule. *Rev Paul Med* 1990;108:236-8.
 10. Araujo Filho VJ, Carlucci Júnior D, de Castro IV, et al. Parathyroid cyst: case report. *Rev Hosp Clin Fac Med Sao Paulo* 1998;53:83-5.
 11. Bürgeser MV, Diller A, Bustos ME, et al. Spontaneous mediastinal hematoma as initial presentation of cystic adenoma of ectopic parathyroid. *Rev Fac Cien Med Univ Nac Cordoba* 2011;68:164-8.
 12. Vasallo M, Bello I, Sánchez N, Melone S, et al. Quiste de paratiroides asociado a carcinoma papilar de tiroides: una rara entidad. *Revista venezolana de cirugía* 2010;63:193-6.
 13. Fuentes Valdés E, Escarpanter González JC, López Díaz A, et al. Radio-guided surgery for removal of a giant parathyroid cyst related to hyperthyroidism. *Revista Cubana de Endocrinología* 2009;20.
 14. McKay GD, Ng TH, Morgan GJ, et al. Giant functioning parathyroid cyst presenting as a retrosternal goitre. *ANZ J Surg* 2007;77:297-304.
 15. Wen HY, Schumacher HR, Zhang LY. Parathyroid disease. *Rheum Dis Clin North Am* 2010;36:647-64.
 16. Sandstrom I. Om en kortel hos mennishkan och atskilliga doggdjus. *Ups Lakafor Forhandl* 1880;14:441-71.
 17. Guner A, Karyagar S, Ozkan O, et al. Parathyroid cyst: the forgotten diagnosis of a neck mass. *J Surg Case Rep* 2011;2011:4.
 18. Johansson H. Parathyroid history and the Uppsala anatomist Ivar Sandström. *Med Secoli* 2009;21:387-401.
 19. Goris D. Extirpation de trios lobules parathyroides kystiques. *Ann Soc Belge Chir* 1905;5:394-400.
 20. Crile G, Perryman RG. Parathyroid cysts; report of five cases. *Surgery* 1953;34:151-4.
 21. McCoy KL, Yim JH, Zuckerbraun BS, et al. Cystic parathyroid lesions: functional and nonfunctional parathyroid cysts. *Arch Surg* 2009;144:52-6; discussion 6.
 22. Armstrong J, Leteurtre E, Proye C. Intraparathyroid cyst: a tumour of branchial origin and a possible pitfall for targeted parathyroid surgery. *ANZ J Surg* 2003;73:1048-51.
 23. Cappelli C, Rotondi M, Pirola I, et al. Prevalence of parathyroid cysts by neck ultrasound scan in unselected patients. *J Endocrinol Invest* 2009;32:357-9.
 24. Wirowski D, Wicke C, Böhner H, et al. Presentation of 6 cases with parathyroid cysts and discussion of the literature. *Exp Clin Endocrinol Diabetes* 2008;116:501-6.
 25. Entwistle JW, Pierce CV, Johnson DE, et al. Parathyroid cysts: report of the sixth and youngest pediatric case. *J Pediatr Surg* 1994;29:1528-9.
 26. Khan A, Khan Y, Raza S, et al. Functional parathyroid cyst: a rare cause of malignant hypercalcemia with primary hyperparathyroidism—a case report and review of the literature. *Case Rep Med* 2012;2012:851941.
 27. Mazeh H, Sippel RS, Chen H. Three large, functioning cystic parathyroid adenomas. *Endocr Pract* 2012;18:e14-6.
 28. Zhu Y, Li NS, Lu L, et al. Hypercalcemic crisis due to a mediastinal parathyroid cyst diagnosed by ultrasound-guided fine needle aspiration. *Chin Med J (Engl)* 2010;123:3731-3.
 29. Mallette LE, Malini S, Rappaport MP, et al. Familial cystic parathyroid adenomatosis. *Ann Intern Med* 1987;107:54-60.
 30. Silverman JF, Khazanie PG, Norris HT, et al. Parathyroid hormone (PTH) assay of parathyroid cysts examined by fine-needle aspiration biopsy. *Am J Clin Pathol* 1986;86:776-80.
 31. Pacini F, Antonelli A, Lari R, et al. Unsuspected parathyroid cysts diagnosed by measurement of thyroglobulin and parathyroid hormone concentrations in fluid aspirates. *Ann Intern Med* 1985;102:793-4.
 32. Sung JY, Baek JH, Kim KS, et al. Symptomatic nonfunctioning parathyroid cysts: role of simple aspiration and ethanol ablation. *Eur J Radiol* 2013;82:316-20.
 33. Katz AD, Dunkleman D. Needle aspiration of nonfunctioning parathyroid cysts. *Arch Surg* 1984;119:307-8.
 34. Akel M, Salti I, Azar ST. Successful treatment of parathyroid cyst using ethanol sclerotherapy. *Am J Med Sci* 1999;317:50-2.
 35. Alberti B, Campatelli A, Antonelli A, et al. Review of a case series of cervical cysts and evaluation of the efficacy of sclerotherapy with tetracycline hydrochloride in thyroid cystic lesions. *Clin Ter* 1994;145:27-33.
 36. Sánchez A, Carretto H. Treatment of a nonfunctioning parathyroid cyst with tetracycline injection. *Head Neck* 1993;15:263-5.
 37. Duque C, Velez A, Penagos A, et al. Caso clínico: Quiste

- Paratirodeo. Revista de la Sociedad Peruana de Cirugía de Cabeza – Cuello y Craneomaxilofacial 2010;1:8-9.
38. Vélez-Hoyos A, Castaño J, Restrepo Z, et al. Presentación de caso. Biopsia aspiración con aguja fina en el diagnóstico de quiste de paratiroides. Medicina & Laboratorio

2005;11:563-6. Available online: <http://www.edimeco.com/medicina-laboratorio/2005/otros-articulos/item/244-presentacion-de-caso-biopsia-aspiracion-con-aguja-fina-en-el-diagnostico-de-quiste-de-paratiroides>

Cite this article as: Román-González A, Aristizábal N, Aguilar C, Palacios K, Pérez JC, Vélez-Hoyos A, Duque CS, Sanabria A. Parathyroid cysts: the Latin-American experience. *Gland Surg* 2016;5(6):559-564. doi: 10.21037/gs.2016.12.08