

Case Report

# Acute liver failure due to white phosphorus ingestion

Oscar Santos;<sup>1</sup> Juan-Carlos Restrepo;<sup>1,2,5</sup> Lina Velásquez;<sup>3</sup> Jaime Castaño;<sup>4</sup> Gonzalo Correa;<sup>1,2,5</sup> Elsy Sepúlveda;<sup>2,5,6</sup> Nora Yepes;<sup>2,5,6</sup> Sergio Hoyos;<sup>2,6</sup> Carlos Guzmán;<sup>2,6</sup> Germán Osorio;<sup>2,7</sup> Andrés Cárdenas<sup>8</sup>

## Abstract

**Background:** White phosphorus is chemical compound available in military ammunition as well as in explosive powder of recreational use. This latter form is commonly found in Latin America and Asia as a main ingredient of gunpowder used to make street firecrackers. Small firecrackers may be ingested accidentally or used as a toxic agent in suicidal attempts which may cause of acute liver failure and death; however the clinical features, incidence and outcome are poorly described in the literature. **Methods:** We describe three cases of white phosphorus intoxication with acute liver failure secondary to the consumption of firecrackers. In two cases, ingestion occurred secondary to suicidal attempts and in one, ingestion occurred by accident. In one case, liver injury improved with supportive care, in the other, the patient required liver transplantation and the third case had a fatal outcome. **Conclusions:** Clinicians providing care of patients with acute hepatitis of unclear etiology should be aware that the ingestion of firecrackers containing white phosphorus might

cause acute liver failure that may require liver transplantation.

**Key words:** Intoxication, white phosphorus, liver failure, liver transplantation.

White phosphorus is an inorganic substance and smoke producing agent made from the chemical element phosphorus. This substance reacts rapidly with oxygen, easily catching fire at temperatures 10 to 15 degrees Celsius above room temperature. White phosphorus is used by the military in the production of ammunition and it is also used to produce phosphoric acid and other chemicals found in fertilizers, food additives, and cleaning compounds. In some countries, variable amounts of white phosphorus are used in the production of firecrackers and fireworks. In our country each firecracker contains between 4 mg to 9 mg of white phosphorus (Toxicology Laboratory of the University of Antioquia - Medellín, Colombia, unpublished data).

Intoxications and burns with white phosphorus are uncommon in the western world and they are originated mainly by labor exposure.<sup>1,2</sup> In developing countries, intoxication can occur due to suicidal attempts or accidental consumption.<sup>3</sup> Severe intoxications are characterized by multisystem organic failure<sup>4</sup> with mortality rates ranging from 20 to 50%.<sup>5,6</sup> The lethal dose after oral ingestion of white phosphorus is 1 mg/kg of body weight, although small amounts as little as 15 mg have resulted in death.<sup>7</sup> Liver failure can occur as a consequence of white phosphorus intoxication,<sup>4,5,8</sup> however there is scarce data of such cases. We describe three cases of white phosphorus intoxication with acute liver failure secondary to the consumption of firecrackers with a different spectrum of clinical manifestations.

## Case 1

A 4 year old girl without significant medical history accidentally ingested 10 street firecrackers. She initially presented with mild abdominal pain, nausea and vomiting and was taken to the local emergency room where she was found to have a normal physical exam. She received intravenous fluids and had a gastric lavage performed

<sup>1</sup> Division of Internal Medicine, Gastroenterology and Hepatology, Hospital Pablo Tobón Uribe.

<sup>2</sup> Gastro-Hepatology Group, University of Antioquia.

<sup>3</sup> Department of Surgery, University Pontificia Bolivariana.

<sup>4</sup> Department of Medicine, University Pontificia Bolivariana.

<sup>5</sup> Division of Liver Transplantation, Hepatobiliary and Pancreatic Surgery, Hospital Pablo Tobón Uribe.

<sup>6</sup> Division of Pediatrics, Hospital Pablo Tobón Uribe.

<sup>7</sup> Department of Pathology, University of Antioquia.

<sup>8</sup> Institut de Malalties Digestives i Metabòliques, Hospital Clinic, University of Barcelona.

Disclosure: The authors declare no conflicts of interest.

Address for correspondence:  
Andrés Cárdenas, MD, MMSc  
Institut de Malalties Digestives i Metabòliques  
University of Barcelona  
Hospital Clinic - Villarroel 170, Esc 3-2  
08036 Barcelona, Spain  
Tel: (+34) 93 227 5753  
Fax: (+34) 93 227 9850  
E-mail: acardena@clinic.ub.es

Manuscript received and accepted: February 25 and March 31, 2009

with saline solution. Her laboratory tests showed a normal complete blood count and normal electrolytes and therefore was discharged. The patient continued to have symptoms of abdominal pain, nausea and vomiting. Two days after the ingestion, she developed jaundice, malaise and weakness and was hospitalized. Laboratory exams showed significant elevation of serum aminotransferases and coagulopathy (Table I). An abdominal ultrasound with Doppler was normal. She also became drowsy and confused and was therefore transferred to our hospital for evaluation of orthotopic liver transplantation (OLT). On admission she was comatose. Physical exam showed jaundice, ascites, hepatomegaly, hyperreflexia, and mydriatic pupils. Serum aminotransferases and bilirubin levels were significantly elevated, and her prothrombin time (PT) was > 100 seconds (Table I). She was diag-

nosed with acute liver failure due to ingestion of white phosphorus. She was listed for emergency OLT and admitted in the Intensive Care Unit (ICU). Her mental status continued to worsen and she had a self limited episode of upper gastrointestinal hemorrhage thought to be related to her underlying coagulopathy. She underwent OLT three days later with a prolonged post-transplant period complicated by nosocomial pneumonia and acute cellular rejection (treated with tacrolimus IV). Histology of the explanted liver showed signs of toxic hepatitis with extensive hepatocyte necrosis and with balloon degeneration (Figure 1). She recovered successfully and was finally discharged 45 days after admission.

## Case 2

Fifteen year old female with a previous history of substance abuse and depression was seen in the outpatient clinic after she ingested 9 firecrackers in a suicidal attempt. One day after the ingestion she developed several episodes of nausea, vomiting and abdominal pain. On physical exam she was alert and well oriented with normal vital signs. There was no jaundice. Heart and lung examination were normal. Her abdomen was soft and nontender with no hepatomegaly or splenomegaly. Her neurologic examination revealed mild asterixis. Laboratory exams revealed a prolonged PT, with normal liver and renal tests (Table I). An abdominal ultrasound with Doppler flow showed no outflow obstruction or liver masses. A presumed acute liver failure secondary to white phosphorus was diagnosed. Therapy with IV fluids was begun and the patient was transferred to the ICU for monitoring. On day 3 the PT rose to 86 seconds, with a significant elevation of aminotransferases elevation and bilirubin (Table II). Physical exam remained unchanged. She was listed for OLT after a thorough discussion with her psychiatrist who gave clearance for the procedure. However, on day 4 the PT remained at 90 seconds, and her clinical status unchanged without any evidence of hepatic encephalopathy. Her liver tests continued to improve slowly over the next 10 days. The patient was discharged after two weeks.

**Table I.** Laboratory exams on admission.

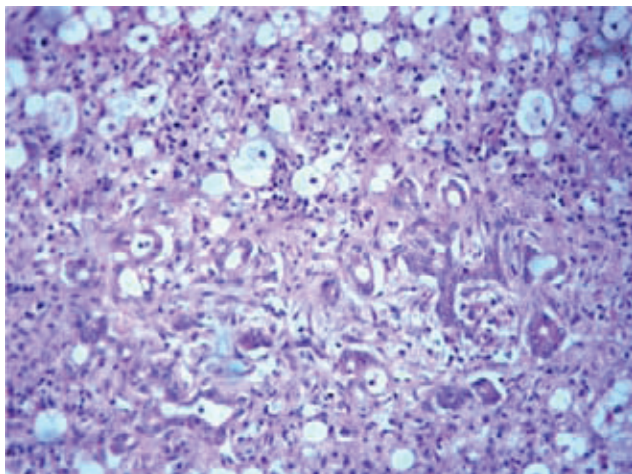
Parameters	Patient 1	Patient 2	Patient 3
Hemoglobin	11.5 g/L	13.1 g/L	17 g/L
WBC count	9,300	10,200	9,200
Eosinophils	3%	0%	2%
Platelet count	198,000	414,000	260,000
PT	> 169 sec	29 sec	146 sec
INR	Infinite	2.6	10
Total bilirubin	8.2 mg/dL	0.6 mg/dL	6.9 mg/dL
Direct bilirubin	5.7 mg/dL	0.3 mg/dL	5.2 mg/dL
Albumin	3.1 g/dL	3.8 g/dL	4.3 g/dL
AST	887 IU	17 IU	1,330 IU
ALT	1,029 IU	21 IU	839 IU
Alkaline phosphatase	561 IU	113 IU	106 IU
Blood urea nitrogen	6 mg/dL	8 mg/dL	7 mg/dL
Creatinine	0.4 mg/dL	0.8 mg/dL	0.9 mg/dL
HAV IgM	Negative	Negative	Negative
Anti-HCV	Negative	Negative	Negative
HBsAg	Negative	Negative	Negative
HBc IgM	Negative	Negative	Negative
Anti-HCV	—	Negative	Negative
Anti-HIV	—	Negative	Negative
HCG pregnancy test	—	Negative	—

WBC: white blood cell, INR: International normalized ratio for prothrombin time (PT), ALT: alanine aminotransferase; AST: aspartate aminotransferase; HAV: hepatitis A virus, Anti-HCV: antibodies to hepatitis C; Anti-HIV: antibodies to human immunodeficiency virus, HBsAg: hepatitis b surface antigen, HBc: hepatitis B core antigen, HCG: human chorionic gonadotropin.

**Table II.** Laboratory exams during admission.

Lab	Day 3			Day 8			Day 15		
	Case 1	Case 2	Case 3	Case 1	Case 2	Case 3	Case 1	Case 2	Case 3
Hemoglobin	9.1	12.7	13.9	11.2	11.5	—	10	10.2	—
WBC	5,800	8,400	9,600	35,000	17,300	—	13,100	9,300	—
Platelets	64,000	345,000	227,000	76,000	241,000	—	180,000	182,000	—
TP	21.2	86	> 169	24.1	26	—	17	12	—
AST	145	430	4,281	131	198	—	57	70	—
ALT	1,039	1,502	1,252	393	165	—	122	75	—
Total bili	4.2	4.5	10	9.8	13.3	—	5.1	10.8	—
Direct bili	2.6	3.4	6.6	6.6	9.7	—	3.6	7.6	—

WBC: white blood cell count, PT: prothrombin time, AST, aspartate aminotransferase; ALT: alanine aminotransferase, bili: bilirubin.



**Figure 1.** Histology of an explanted liver of a patient that developed liver failure after the ingestion of street firecrackers containing white phosphorus which showed signs of toxic hepatitis with extensive hepatocyte necrosis along with balloon degeneration.

### Case 3

A 32 year old male on a suicidal attempt ingested 12 firecrackers and 12 hours later developed abdominal pain, nausea and vomiting. Two days later he was seen at his local hospital with worsening abdominal pain and continuous vomiting and was therefore transferred to our hospital for further evaluation. On admission, he had jaundice, minor changes in mental status and asterixis. Heart and lung examination were normal. His abdomen was nontender without hepatomegaly or splenomegaly. Laboratory tests revealed direct hyperbilirubinemia (total bilirubin 6.9 mg/dL), and increased AST and ALT > 20 times upper limit of normal, PT of 146 seconds (*Table I*). An abdominal ultrasound with Doppler showed no abnormalities. He was managed as acute liver failure secondary to white phosphorus. He was transferred to the ICU for monitoring and supportive treatment. The following day he had worsening of renal function, oliguria and severe metabolic acidosis. He was placed on venovenous dialysis. His liver function continued to worsen and he developed grade II encephalopathy (West-Haven criteria). The patient's clinical status remained unchanged and despite improvement of his acidosis, his renal and hepatic function worsened. He progressed to grade III encephalopathy, developed severe coagulopathy with upper gastrointestinal bleeding requiring mechanical ventilation and vasopressor therapy. Despite all these measures the patient died 3 days after admission.

### Discussion

White phosphorus is a highly toxic element that can be absorbed by the gastrointestinal tract, the respiratory tract, the skin, and the mucous membranes. It is evenly

distributed and incorporated in several tissues, particularly the liver.<sup>9,10</sup> A dose of 15 mg can be highly toxic and if more than 50 mg are ingested it is fatal (1 mg / kg on the average).<sup>7</sup> The toxicity of white phosphorus may occur due to alteration of the ribosomal function and the synthesis of proteins,<sup>13</sup> loss of regulation of the blood glucose and the glycogen deposits<sup>14</sup> and to the alteration of lipoprotein synthesis and secretion of triglycerides, leading to intracellular accumulation and fatty degeneration of multiple organs, especially the liver, the kidney, the heart and brain.<sup>7,11,12</sup> White phosphorus intoxication produces multiple signs and symptoms which have been divided in stages.<sup>4</sup> Stage I (General symptoms): Occurs during the first 24 hours after ingestion and is characterized by epigastric abdominal pain, profuse diarrhea, nausea, vomiting and in some cases fever. The breath, vomit and burps have garlicky scent but this not always this present. The laboratory tests in this stage are normal. Stage II (Asymptomatic): Occurs between 24 and 72 hours after ingestion. It is an asymptomatic period; however the histology of liver in this stage demonstrates early changes of toxic hepatitis and laboratory data shows mild elevation of aminotransferases and bilirubin. Stage III (Advanced): After 72 hours until the resolution of the symptoms or death. This stage is characterized by multi-systemic organic failure. There is acute hepatitis; liver histology shows steatohepatitis and necrosis.<sup>8</sup> Patients may present with acute liver failure with encephalopathy, coagulopathy and abnormal liver tests.<sup>6-8,11</sup> In some patients, depending on the ingested quantity of white phosphorus and for unknown reasons; the initial insult resolves spontaneously.<sup>13</sup> In some cases renal failure ensues and patients develop with oliguria and acute tubular necrosis. The effects on the central nervous system are mainly the alteration of the mental status with irritability, confusion, psychosis, allucinations and coma. Patients may also develop hypotension, tachycardia, arrhythmias and cardiogenic shock.<sup>11,14</sup>

There is no specific diagnostic test and blood phosphorus levels are not useful.<sup>4</sup> Thus diagnosis is one of exclusion after taking a detailed history and physical exam. In these three cases described above, viral, autoimmune, metabolic, and other hepatotoxic causes were excluded, and additionally abdominal ultrasonography with Doppler showed no liver masses, outflow obstruction, or biliary tract obstruction. We performed an extensive work-up to exclude other causes of acute severe hepatitis and only after all tests were negative we suspected white phosphorus to be the cause of hepatotoxicity. The temporal association between the ingestion of firecrackers, the development of symptoms, the elevation of liver enzymes and bilirubin (in case 1 and 3) as well as the exclusion of other causes suggested the possibility of an acute toxic-induced hepatitis.

Unfortunately there is no antidote or specific treatment for white phosphorus intoxication. Gastric lavage

(with saline solution and potassium permanganate which can oxidize the phosphorus) should be performed in all cases if possible.<sup>4</sup> Other substances for lavage such as solutions of copper sulfate and mineral oil, have been recommended but their clinical utility has not been well demonstrated.<sup>5,6</sup> Since severe intoxications with white phosphorus can evolve quickly to an acute liver failure and multisystemic organic failure, it is recommended patients be admitted to the ICU with continuous monitoring and supportive measures. Liver transplantation should be performed in suitable candidates according to previous defined criteria (i.e. King's College) for acute liver failure.<sup>15</sup> Intravenous steroids and exchange transfusion were previously used in 49 patients with an acute intoxication due to white phosphorus; however this treatment strategy did not appear to prevent the onset of coma in this type of liver injury and did not increase survival after development of coma.<sup>16</sup>

In conclusion, ingestion of firecrackers containing white phosphorus may cause non-specific gastrointestinal symptoms and acute hepatitis with severe prolongation of the prothrombin time that may resolve spontaneously, require liver transplantation or result in death. Physicians caring for patients with acute hepatitis of unclear etiology should be aware that the ingestion of firecrackers containing white phosphorus might cause liver failure that may require liver transplantation.

## References

1. Konjoyan TR: White phosphorus burns: Case report and literature review. *Milit Med* 1983; 148: 881-884.
2. Mozingo DW, Smith AA, McManus WF, et al. Chemical burns. *J Trauma Inj Crit Care* 1988; 28: 642-647.
3. Noguera A, Cato-David A. Intoxicaciones agudas por fósforo blanco. *Rev Med y Cirugia* 1966; 1: 209-18.
4. Brent J, Wallace K, Buckhart K. Phosphorus. In: Brent J, Wallace K, Buckhart K, eds. *Critical care toxicology: diagnosis and management of the critically poisoned patient*. Elsevier Saunders 2005: 851-861.
5. Diaz-Rivera RS, Collazo PJ, Pons ER, Torregosa MV. Acute phosphorus poisoning in man: A study of 56 cases. *Medicine* 1950; 29: 269-298.
6. McCarron MM, Gaddis GP, Trotter AT. Acute yellow phosphorus poisoning from pesticide pastes. *Clin Toxicol* 1981; 18: 693-711.
7. Agency for Toxic Substances and Disease Registry (ATSDR). US Department of Health and Human Services, Public Health Service. Toxicological profile for white phosphorus. 1997. <http://www.atsdr.cdc.gov/tfacts103.html> (accessed September 12, 2008).
8. Fernandez OU, Canizares LL. Acute hepatotoxicity from ingestion of yellow phosphorus-containing fireworks. *J Clin Gastroenterol* 1995; 21: 139-142.
9. Cameron JM, Patrick RS. Acute phosphorus poisoning-the distribution of toxic doses of yellow phosphorus in the tissues of experimental animals. *Med Sci Law* 1966; 6: 209-214.
10. Winek CL, Collom WD, Fusia EP. Yellow phosphorus ingestion-three fatal poisonings. *Clin Toxicol* 1973; 6: 541-545.
11. Seakins A, Robinson DS. Changes associated with the production of fatty livers by white phosphorus and by ethanol in the rat. *Biochem J* 1964; 92: 308-312.
12. Ghoshal AK, Porta EA, Hartroft WS. The role of lipoperoxidation in the pathogenesis of fatty livers induced by phosphorus poisoning in rats. *Am J Pathol* 1969; 54: 275-291.
13. Chretien TE. Acute phosphorus poisoning: Report of a case with recovery. *N Engl J Med* 1945; 223: 247-29.
14. Talley RC, Linhart JW, Trevino AJ. Acute elemental phosphorus poisoning in man: cardiovascular toxicity. *Am Heart J* 1972; 84: 139-140.
15. Polson J, Lee WM. AASLD Position paper: The management of acute liver failure. *Hepatology* 2005; 41: 1179-1197.
16. Marin GA, Montoya CA, Sierra JL, Senior JR. Evaluation of corticosteroid and exchange-transfusion treatment of acute yellow-phosphorus intoxication. *N Engl J Med* 1971; 284: 125-128.