

CASE REPORT

DOI: <http://dx.doi.org/10.15446/revfacmed.v66n4.66940>

Late diagnosis of pseudohypoparathyroidism in adulthood. Case series

Pseudohipoparatiroidismo diagnosticado tardíamente en la adultez, una serie de casos

Received: 09/08/2017. Accepted: 13/12/2017.

María Camila Trejo¹ • Alejandro Román-González^{1,2} • Sebastián Ruíz¹ • Catalina Tobón¹ • Pablo Castaño¹ • Clara Arango^{1,3}
Carolina Prieto³¹ Universidad de Antioquia - Faculty of Medicine - Department of Internal Medicine - Medellín - Colombia² Hospital Universitario San Vicente Fundación - Department of Endocrinology and Metabolism - Medellín - Colombia.³ Hospital Pablo Tobón Uribe - Department of Endocrinology - Medellín - Colombia.

Corresponding author: Alejandro Román-González. Department of Endocrinology and Metabolism, Hospital Universitario San Vicente Fundación. Calle 64 No. 51D-154, Oficina de Docencia. Telephone number: +57 4 4441333, ext.: 3638. Medellín. Colombia. Email: alejoroman@gmail.com.

[| Abstract |](#)

Introduction: Pseudohypoparathyroidism (PHP) is a rare hereditary disease, characterized by hypocalcemia/hyperphosphatemia secondary to peripheral resistance to parathyroid hormone (PTH). PHP diagnosis is usually precluded since hypocalcemia is considered as the primary diagnosis, thus delaying further diagnostic studies and preventing an adequate management of this clinical condition.

Materials and methods: Retrospective review of the databases of the Endocrinology departments of two tertiary care centers of Medellín, Colombia from January 2012 to December 2016. Patients diagnosed with PHP based on clinical presentation and confirmatory laboratory values were included.

Results: Four patients met the inclusion criteria. All PHP cases were diagnosed in adulthood despite strong early clinical and laboratory evidence of the disease. Three patients were diagnosed with Fahr's syndrome and two with Albright's hereditary osteodystrophy. The mean values obtained were PTH of 376.8 pg/mL, calcium of 6.17 mg/dL and phosphorus of 6.55 mg/dL.

Conclusions: PHP is a rare disorder. This paper describes four PHP cases diagnosed during adulthood. Emphasis should be placed on the judicious approach to the patient with hypocalcemia and hyperphosphatemia with increased PTH and normal renal function, since these symptoms strongly suggest a diagnosis of PHP.

Keywords: Pseudohypoparathyroidism; Parathyroid Diseases; Hypocalcemia; hyperphosphatemia (MeSH).

[| Resumen |](#)

Introducción. El pseudohipoparatiroidismo (PHP) es una condición rara caracterizada por hipocalcemia e hiperfosfatemia secundarias a resistencia periférica a la hormona paratiroidea (PTH). Es frecuente que la hipocalcemia sea establecida de forma equivocada como diagnóstico primario y que el diagnóstico definitivo de PHP sea tardío, difiriendo los estudios y el manejo específico que exigen estos pacientes.

Materiales y métodos. Se revisaron de forma retrospectiva las bases de datos de endocrinología de dos centros terciarios de Medellín, Colombia, desde enero de 2012 a diciembre de 2016. Se incluyeron pacientes con diagnóstico de PHP por presentación clínica y valores confirmatorios de laboratorio.

Resultados. Cuatro pacientes cumplieron los criterios de inclusión. Todos los casos fueron diagnosticados en la adultez a pesar de tener evidencia temprana, clínica y bioquímica de la enfermedad. Tres pacientes tenían síndrome de Fahr y dos tenían osteodistrofia hereditaria de Albright. Los valores medios registrados fueron PTH de 376.8 pg/mL, calcio de 6.17 mg/dL y fósforo de 6.55 mg/dL.

Conclusiones. El PHP es un trastorno raro; se describen cuatro casos diagnosticados de forma tardía en la adultez. Se enfatiza en el enfoque juicioso del paciente con hipocalcemia, la cual, en presencia de hiperfosfatemia con PTH elevada y función renal normal, debe hacer sospechar el diagnóstico de PHP.

Palabras clave: Pseudohipoparatiroidismo; Enfermedades de las paratiroides; Hipocalcemia; hiperfosfatemia (DeCS).

Trejo MC, Román-González A, Ruíz S, Tobón C, Castaño P, Arango C, *et al.* Late diagnosis of pseudohypoparathyroidism in adulthood. Case series. Rev. Fac. Med. 2018;66(4):643-49. English. doi: <http://dx.doi.org/10.15446/revfacmed.v66n4.66940>.

Trejo MC, Román-González A, Ruíz S, Tobón C, Castaño P, Arango C, *et al.* [Pseudohipoparatiroidismo diagnosticado tardíamente en la adultez, una serie de casos]. Rev. Fac. Med. 2018;66(4):643-49. English. doi: <http://dx.doi.org/10.15446/revfacmed.v66n4.66940>.

Introduction

Pseudohypoparathyroidism (PHP) is a rare, heterogeneous and hereditary condition characterized by peripheral resistance to parathyroid hormone (PTH). (1) Its onset usually occurs during childhood with clinical manifestations of hypocalcemia and laboratory studies that reveal hypocalcemia and hyperphosphatemia. These studies, added to elevated serum PTH concentrations, allow establishing the initial diagnosis. Some patients are diagnosed earlier through genetic studies because they have a close relative affected by this condition.

Although the role of PHP in the diagnostic approach to hypocalcemia is clear (2), it often goes unnoticed even when frankly suggested by symptoms, laboratory tests, and neuroimaging findings. This situation delays studies, counseling, and the specific management of this entity.

The biochemical profile is the same in all PHP cases, but its clinical presentation may vary according to the specific genetic defect and the imprinting pattern. Albright's hereditary osteodystrophy (AHO) is a phenotype that consists of skeletal anomalies including rounded facies, obesity, short stature, subcutaneous ossifications and brachydactyly, which are observed in types 1a and 1c, as well as pseudopseudohypoparathyroidism (PPHP), which is absent in types 1b and 2. (1)

Other clinical manifestations, besides those associated with the typical phenotype, are derived from hypocalcemia and elevated calcium-phosphorus product, such as Fahr's syndrome, which consists of secondary gangliobasal calcifications.

This paper presents four cases of patients with a late diagnosis of PHP despite long-standing symptomatic hypocalcemia and clear evidence of the disease reported in their clinical history; two of them had AHO, three presented Fahr's syndrome, and pathological fractures were present in one of the cases.

This series of cases intends to call the attention of emergency physicians and outpatient consultation doctors regarding the mandatory character of a judicious approach to hypocalcemia, which is a finding but not a diagnosis. In addition, it also seeks to highlight the relevance of knowing how to interpret the biochemical profile of calcium-phosphorus metabolism in a specific clinical setting and highlight PHP as a diagnostic possibility for all patients with hypocalcemia, regardless of its severity and presentation.

Materials and methods

The inter-consultation and consultation databases of the Endocrinology Service of two tertiary care hospitals of Medellín, Colombia, were reviewed retrospectively from January 2012 to December 2016. The institutions were Hospital Universitario San Vicente Fundación and Hospital Pablo Tobón Uribe.

Patients diagnosed with PHP due to clinical presentation and confirmatory laboratory values (PTH, calcium and phosphorus levels) were included. Patients with other parathyroid diseases such as primary, secondary or tertiary hyperparathyroidism and all hypoparathyroidism cases were excluded. A database was designed including the most important clinical variables of PHP, finding four cases (Table 1). The IBM SPSS Statistics V21 software and Microsoft Excel 2016 were used to analyze the data obtained. The study was approved by the Research and Ethics Committee of Hospital Pablo Tobón Uribe (Minutes 12/2018 of June 28 2018) and the Research Ethics Committee of the Hospital Universitario San Vicente Fundación (Minutes 21-2918 of July 13 2018).

Continuous variables are presented as mean and standard deviations (σ), while categorical variables are presented as frequencies and proportions.

Table 1. Relevant diagnostic information.

Information	Case 1	Case 2	Case 3	Case 4	Final aggregate
Reason for consultation	Hypocalcemia	Convulsion	Convulsion Pathologic fracture Hypocalcemia	Hypocalcemia	Hypocalcemia (100%) Convulsion (50%)
History	Epilepsy	Epilepsy	Mother with AHO	Hypothyroidism	-
AHO	No	No	Yes	Yes	AHO 50%
Age	22	23	21	25	-
PTH pg/mL	373.3	416.4	398	319.7	376.8 ($\sigma=41.99$)
Calcium mg/dL	5.8	5.2	5	8.68	6.17 ($\sigma=1.70$)
Phosphorus mg/dL	8.85	6.5	6.2	4.66	6.55 ($\sigma=1.73$)
25(OH)D ug/dL	-	34	-	19.6	26.8 ($\sigma=10.18$)
Magnesium mg/dL	1.92	1.65	1.72	-	1.76 ($\sigma=0.14$)
TSH mU/mL	5.02	3.63	2.89	5.58	4.2 ($\sigma=1.23$)
Free T4	1.16	0.85	1.14	1.97	1.28 ($\sigma=0.48$)
Magnetic resonance	Bilateral and symmetric intracranial calcifications Predominance in basal ganglia/normal EEG			-	Calcifications 75%
Diagnostic	PHP 1B/2 Fahr's syndrome RTH	PHP 1B/2 Fahr's syndrome Tubulopathy	PHP 1A/1C Fahr's syndrome	PHP 1A/1C; Hypothyroidism	-

AHO: Albright's hereditary osteodystrophy; PTH: intact parathyroid hormone; TSH: thyroid stimulating hormone; PHP: pseudohypoparathyroidism; RTH: resistance to thyroid hormone.

Source: Own elaboration.

Case presentation

Case 1

22-year-old man referred by the Neurology service to the Endocrinology service to conduct studies of hypocalcemia, with no perinatal neuroinfection or neurotrauma history, and neurodevelopment referred to as normal. The patient was diagnosed with epilepsy at 13 years of age after an episode of generalized tonic-clonic seizure and therapeutic failure with valproic acid, gabapentin and levetiracetam. Also, the subject had a presumptive diagnosis of Fahr’s disease with extrapyramidal symptoms managed with risperidone.

During consultation with Endocrinology, the patient reported symptoms of anxiety, paresthesia and involuntary movements in the lower limbs. Physical examination showed normal vital signs; AHO, Trousseau’s and Chvostek’s signs were negative. Paraclinical tests revealed hypocalcemia and persistent hyperphosphatemia with elevated PTH, and normal magnesium and renal function, which led to the diagnosis of PHP. Other hormonal axes were studied; subclinical hypothyroidism was reported given the discrete elevation of TSH with FT4 in normal range, and the corticotropic axis was normal. The patient did not have an AHO phenotype, so partial resistance to thyroid hormones was considered as possible and a PHP type 1b as more likely (Table 2).

Table 2. Classification of pseudohypoparathyroidism and differential diagnosis.

Classification	Hormone resistance	AHO	GNAS defect	PTH infusion
PHP 1a	Multiple: PTH, TSH, Gn, GnRH	Yes	Maternal mutation	↓ cAMP ↓ Phosphaturia
PHP 1b	PTH, TSH *	No	Imprint	↓ cAMP ↓ Phosphaturia
PHP 1c	Multiple: PTH, TSH, Gn	Yes	Maternal mutation	↓ cAMP ↓ Phosphaturia
PHP 2	PTH	No	Unknown	Normal cAMP ↓ Phosphaturia
PPHP	No	Yes	Paternal mutation	Normal

PHP: pseudohypoparathyroidism; AHO: Albright’s hereditary osteodystrophy; PTH: parathormone; TSH: thyroid-stimulating hormone; Gn: gonadotropins; GnRH: gonadotropin-releasing hormone; GNAS: guanine nucleotide binding protein, alpha stimulating; PPHP: pseudo-pseudohypoparathyroidism.

* Some cases

↓ Low/decreased

Source: Own elaboration based on Tafaj *et al.* (3).

Magnetic resonance imaging (MRI) revealed hyperintensity of the putamen and head of the caudate on the FLAIR sequences, and hyperintensity in the pulvinar of the thalamus. Gradient echo sequences showed a tendency to calcification of the deep cerebellar gray nuclei, the pale globe and some subcortical regions. Given the recent diagnosis of alterations of calcium metabolism secondary to PHP, these findings were clearly compatible with Fahr’s syndrome. Treatment with calcium carbonate and calcitriol was prescribed, as well as joint follow-up by Neurology and Endocrinology.

Four years after his diagnosis, the patient remains adherent to medical management and has not presented new convulsive episodes, although some extrapyramidal symptoms still persist. The most recent known laboratory tests reveal acceptable levels of calcium (8.7 mg/dL) and phosphorus (4.38 mg/dL), as well as persistent elevated PTH (460 pg/mL).

Case 2

23-year-old woman with a history of epilepsy since she was 15 years old, who reported presenting five generalized tonic-clonic convulsive episodes and no medical treatment. At the age of 20, hypocalcemia of unknown etiology was discovered through routine laboratory studies, so calcium carbonate was prescribed, which the patient took intermittently. The woman had no relevant family history and was admitted to the emergency department due to a new generalized tonic-clonic seizure episode; during the review of systems, she described suffering from generalized paresthesia for several months.

Physical examination showed tongue with a fissure in the right lateral region due to bite and erythema in the right patella due to contusion, both secondary to the convulsive episode; Trousseau’s and Chvostek’s signs were negative. Paraclinical tests taken on admission —which included hemoleucogram, ionogram, renal and hepatic function— revealed hypokalemia (2.8 meq/L) and hypocalcemia (5.2 mg/dL; corrected with albumin 5 g/dL), and normal magnesium and renal function, for which substitution was initiated with potassium gluconate and calcium carbonate. A CT brain scan was performed, exposing multiple supra and infratentorial calcifications, predominantly in the bilateral basal ganglia region and the thalami; these findings were confirmed by a brain MRI that suggested Fahr’s disease as a diagnostic possibility.

Considering this clinical scenario, in-hospital endocrinology assessment was requested to study hydroelectrolytic alterations associated with a possible Fahr’s syndrome. Endocrinology requested more laboratory studies that showed hypocalcemia and hyperphosphatemia with elevated PTH, normal 25-hydroxy vitamin D and normal renal function, leading to a diagnosis of PHP. Other relevant laboratory tests included normal thyroid profile and phosphaturia in inappropriately normal levels (phosphorus in urine) over a 24-hour period: 0.51gr; reference value 0.4-1.3; phosphaturia 23.1 mg/dL).

Regarding the classification of PHP (Table 2), given that the patient did not have an AHO phenotype, it was likely to be type 1B or 2; evidence of non-resistance to other hormones supported type 2. On the other hand, brain imaging findings in the presence of calcium metabolism alterations, convulsive syndrome and secondary extrapyramidal symptoms make up Fahr’s syndrome.

In addition, the Nephrology service was asked to expand the study of hypokalemia, regarded as secondary to loss of kidney function. Associated tubulopathy was proposed as etiology, although a definitive diagnosis was not established.

During hospitalization, the patient remained asymptomatic, received oral supplementation with calcitriol 0.5µg every 12 hours and calcium carbonate 600mg every 8 hours until stable concentrations of calcium and phosphorus were achieved. She was discharged with prescription for outpatient treatment that included oral potassium supplement intake. The patient remained adherent to medical management, without new convulsive episodes, calcium in 8.3 mg/dL and potassium in 3.8 mg/dL as goals, but with persistent elevated phosphorus (5.3 mg/dL), and constant joint follow-up by the Endocrinology and Nephrology services.

Case 3

21-year-old man with no significant personal or perinatal history, and without previous neuroinfection or neurotrauma. Relevant family history included short stature and shortening of the fourth and fifth metacarpal and metatarsal on the part of the mother.

The patient was taken to the emergency service after experiencing a tonic-clonic seizure episode, falling from his own height, and

inability to walk after the event. On admission, fracture of the right hip was documented, which was managed with osteosynthesis without complications. Paraclinical tests taken on admission (complete blood count, ionogram, renal and hepatic function) showed severe hypocalcemia (5 mg/dL), which required a referral to the Endocrinology service.

During the endocrinology consultation, the patient reported general malaise and generalized paresthesia over the last week prior to the consultation. Physical examination revealed as important findings short stature, overweight, shortening of the fourth and fifth metatarsal and metacarpal (Figure 1) and positive Archibald's and Trousseau's signs.

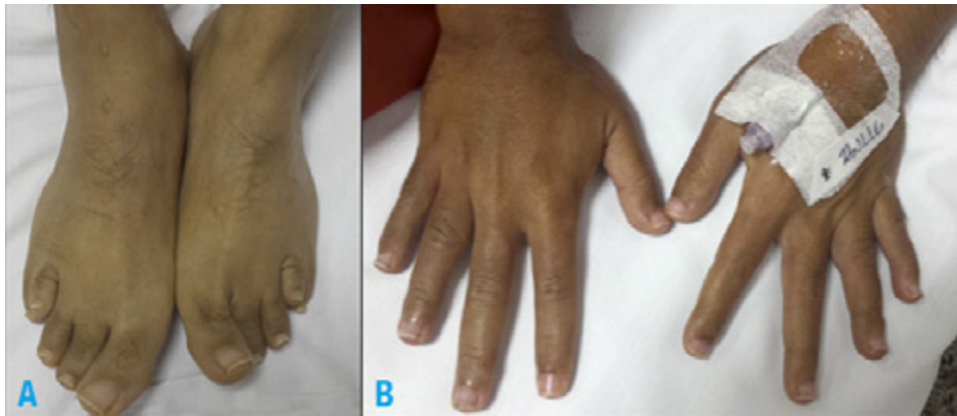


Figure 1. Phenotypic features of Albright's hereditary osteodystrophy, case 3. A) shortening of the fourth and fifth metatarsal; B) shortening of the fourth and fifth metacarpal.

Source: Documents obtained during the study.

In addition, a brain tomography was performed, which revealed bilateral calcifications in the basal, thalamic and subcortical nuclei compatible with Fahr's syndrome.

These phenotypic clinical findings of AHO, in the context of hypocalcemia and hyperphosphatemia with elevated PTH, are compatible with the diagnosis of PHP type 1a/1c (Table 2).

During his hospitalization, the patient remained asymptomatic and received supplements with calcium and calcitriol orally, with daily biochemical monitoring until stable levels were achieved. He was discharged with prescription for outpatient treatment and follow-up with Endocrinology. During his last appointment, two years after the diagnosis of PHP, he reported remaining asymptomatic; calcium (10.9 mg/dL) and phosphorus (4.46 mg/dL) levels were found within target, so it was decided to continue the same medical management.

Case 4

25-year-old woman referred to the Endocrinology service for evaluation of hypocalcemia with a history of hypothyroidism treated with levothyroxine, as well as treatment with calcium, vitamin D and calcitriol supplementation due to hypocalcemia and vitamin D deficiency detected in ambulatory paraclinical tests requested by a general practitioner. No relevant family history was reported.

The patient denied symptoms that could suggest hypocalcemia and Fahr's syndrome. Physical examination showed normal vital signs and, as positive findings, short stature, overweight and shortening of the third and fourth metacarpal and metatarsal (Figure 2); Trousseau's and Chvostek's signs were negative. Her medical history included a paraclinical test taken one year before consultation in which hypocalcemia, 25-hydroxy vitamin D deficiency and elevated PTH were reported, findings compatible with a diagnosis of PHP, which suggested subtype 1a/1c in the presence of phenotypic traits of AHO and resistance to thyroid hormones (Table 2). Additional studies showed normal gonadotropic axis, normal karyotype and normal thyroid ultrasound. The patient continued in follow-up with Endocrinology, and remained adherent to medical management and asymptomatic.

Discussion

PHP is comprised of a heterogeneous group of rare diseases and has an estimated prevalence of 0.79 per 100 000 inhabitants. (3) It is characterized by peripheral resistance to the action of PTH, a hormone produced and secreted by the parathyroid glands in response to low serum calcium levels, whose main function is to maintain the homeostasis of calcium-phosphorus metabolism. (4)

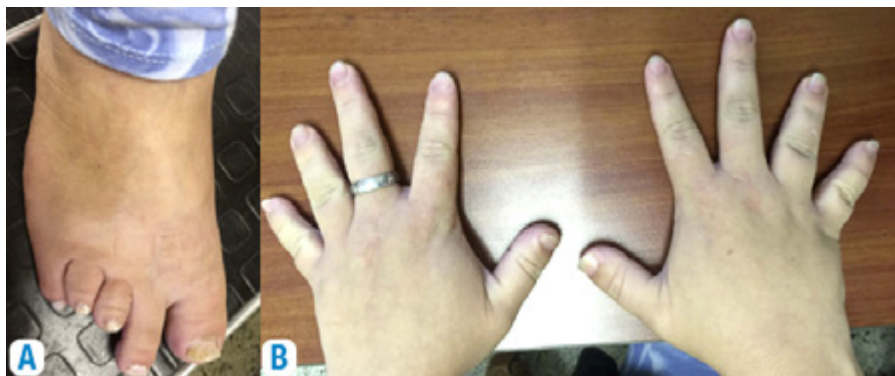


Figure 2. Phenotypic traits of Albright's hereditary osteodystrophy, case 4. A) shortening of the third and fourth metatarsal; B) shortening of the third and fourth metacarpal.

Source: Documents obtained during the study.

PHP is an entity with autosomal dominant inheritance and genomic imprinting. The defect that prevents the action of PTH derives from genetic or epigenetic alterations in the GNAS (guanine nucleotide binding protein, alpha stimulating) locus (5) and in the long arm of chromosome 20 (20q13.3), which encodes the alpha subunit of the Gs protein (G stimulator) to which the PTH receptor is coupled (PTH1R). (3,6,7)

Laboratory tests show hypocalcemia and hyperphosphatemia, with normal renal function and elevated serum concentrations of PTH. (4) In PHP, the main site of resistance to PTH is the proximal renal tubule and, as a direct result, hyperphosphatemia and low concentrations of 1,25 dihydroxyvitamin D (1,25(OH)₂D) are observed, the latter being the main cause of hypocalcemia; this, in turn, increases the PTH and worsens hyperphosphatemia. Since PTH responses in the bone and distal renal tubule are preserved, high levels of PTH could partially prevent symptomatic hypocalcemia by mobilizing calcium from the bone and increasing renal calcium reabsorption. (8)

Clinical manifestations may vary according to the genetic defect and the imprinting pattern under which this is expressed. (9) A phenotype compatible with AHO may be observed, characterized by rounded facies, obesity, short stature, ectopic ossification and brachydactyly. (6) Other clinical manifestations, besides those related to the typical phenotype, are derived from hypocalcemia and the high calcium-phosphorus product.

PHP is classified into different subtypes based on the phenotype, the hormonal resistance pattern, the genetic defect and the renal response to exogenous PTH infusion. (Table 2) The phenotype is defined by the presence or absence of AHO, and hormone resistance is determined by the resistance to other hormones dependent on the G α protein system, such as TSH, gonadotropins or GH. (10) PPHP presents the typical AHO phenotype in an isolated manner, without biochemical alterations in the phosphocalcic profile since there is no resistance to the action of PTH. (4)

The renal response to PTH infusion is explained by the normal capacity of formation of cyclic adenosine monophosphate (cAMP)

before the stimulation of the PTHR1 receptor, which is coupled to Gs proteins with high concentrations of expected cAMP in healthy subjects. In PHP, this response is variable: it is preserved in type 2 and absent in type 1, despite the fact that the phosphaturic response is deficient in both types, indicating a defect distal to the generation of cAMP in PHP2. (7,8)

In general, patients with PHP first experience signs and symptoms of hypocalcemia, which depend on its chronicity and severity. Hypocalcemia is usually established as a primary diagnosis, which delays the diagnosis of PHP, even in the presence of suggestive clinical evidence and secondary Fahr's syndrome in up to 80% of patients. This syndrome consists of the presence of brain calcifications, predominantly in the basal ganglia, in the context of an alteration of calcium metabolism; it also manifests with convulsive syndromes, extrapyramidal symptoms and neuropsychiatric disorders. (11-13) Ectopic calcifications may develop as a consequence of late diagnosis and treatment, being the presence of cataracts, cochlear and subcutaneous calcifications more commonly observed.

The four cases described here correspond to adult patients (Table 1) whose reason for initial consultation, despite being associated with symptomatic hypocalcemia, did not lead to an assertive diagnosis. The definitive diagnosis of PHP was made years after the clinical onset of the disease in tertiary care institutions with an Endocrinology service. Of the cases reported, three (cases 1, 2 and 3) met the criteria for Fahr's syndrome, which emphasizes the late nature of the diagnosis. (14) The diagnostic approach of each case was made based on hypocalcemia (Figure 3) (2,15), which suggests the diagnosis of PHP when associated with hyperphosphatemia and elevated PTH.

PHP is diagnosed after other conditions have been discarded, and PHP1 and PHP2 have been classically differentiated based on the renal response to the exogenous PTH infusion. Urinary phosphate excretion is altered in both types, while cAMP is only decreased in PHP1. However, because of the lack of availability of this measurement in our context, resistance to TSH could guide the classification in the absence of the AHO phenotype. PHP classification does not change the therapeutic behavior.

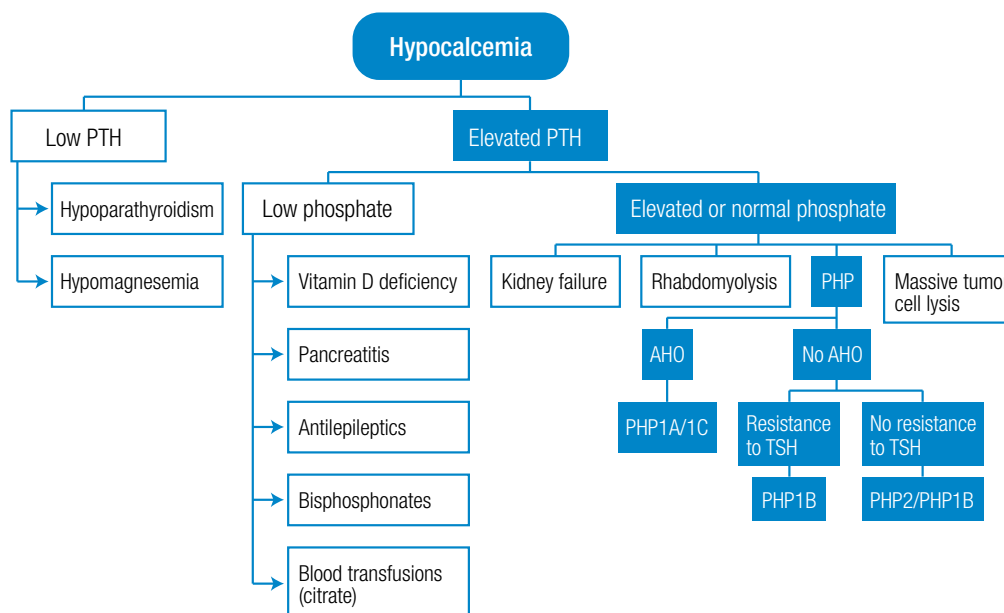


Figure 3. Diagnostic approach to PHP. PTH: parathormone; PHP: pseudohypoparathyroidism; AHO: Albright's hereditary osteodystrophy; TSH: thyroid stimulating hormone.

Source: Elaboration based on Tafaj *et al.* (3).

Differential diagnosis includes other entities with a laboratory profile similar to PHP such as renal disease (whether chronic or acute), which is easily discarded by measuring creatinine, and osteomalacia, which presents with hypocalcemia and PTH elevation; contrary to this, PHP occurs with hypophosphatemia.

With respect to the PHP subtype (Figure 3 and Table 2), although urinary cAMP measurement or genetic studies were not carried out in any of the patients described, it was possible to achieve an initial approximation based on the phenotype and the hormonal resistance profile. In this regard, cases 3 and 4 present phenotypic features of AHO (short stature and round face), while case 3 shows shortening of the fourth and fifth metacarpals, and case 4, brachydactyly. In the presence of resistance to PTH and AHO, the probable diagnosis is PHP type 1a or 1c; however, for a definitive classification, it is necessary to carry out genetic studies that are not available in Colombia. On the other hand, cases 1 and 2 present a PHP biochemical profile without signs compatible with AHO, suggesting PHP type 1b or 2. The definitive classification requires genetic studies; however, the profile of multiple hormonal resistance of case 1, resistance to PTH and TSH, supports the diagnosis of type 1a.

The treatment of PHP consists in the administration of active metabolites of vitamin D, ideally calcitriol, with or without oral calcium supplement and with dose adjustment until achieving a calcium level in the normal range. (16) Because some tissues are not resistant to PTH, elevated PTH levels may be sufficient to maintain normal calcium levels in some patients with PHP1; however, as far as possible, the treatment should be aggressive enough to normalize PTH levels and avoid the potential effects of bone demineralization. (17) In the reported cases, all patients received calcium and calcitriol supplementation, which led to achieve normal calcium levels and symptomatic improvement.

As mentioned above, the aim of this series of cases is to describe the clinical diversity of PTH and to emphasize the importance of the basic approach using laboratory tests in patients with symptomatic hypocalcemia; a calcium-phosphorus profile properly interpreted should lead to an accurate diagnosis and timely treatment of PHP.

There are only two publications available in the literature in Colombia. The first is a report by Ucros *et al.* (18) about a family of three siblings with AHO phenotype, hypocalcemia and lack of response to PTH, which was published in 1957, and the second is a manuscript by Bernal *et al.* (19) that describes the case of a 5-year-old girl with short stature, AHO phenotype, cataracts, neurodevelopmental delay, seizures and hypocalcemia. In Latin America, after a search in LILACS, 41 reported cases were found, 5 of which were described in a Brazilian publication (20); other cases have been reported in Chile, Mexico and Venezuela. In world literature, Underbjerg *et al.* (21), reported in 2016 a series of 60 cases, the largest on PHP published; the median age at which the diagnosis was established in this series was 13 years, much lower than the age of the 4 cases presented here, which was 22.5 years.

This report, besides being the largest series of cases published in Colombia, is interesting because it presents patients who were diagnosed with PHP in adulthood, even though this is an inherited disorder with early clinical onset. This proves that there are shortcomings in the diagnostic approach to patients with hypocalcemia and, perhaps, that calcium disorders are underdiagnosed and sometimes overlooked as a differential diagnosis of frequent clinical expressions, such as seizures and other neuromuscular symptoms.

Conclusions

Hypocalcemia is not a diagnosis, but a laboratory finding that requires optimizing efforts to find its etiology. Although PHP is a

rare possibility, it should be considered in the diagnostic algorithm. The diagnosis of PHP can be achieved based on a judicious approach to hypocalcemia.

Hypocalcemia along with hyperphosphatemia in the presence of elevated PTH with normal renal function are findings that confirm PHP. Although its strict classification requires genetic studies, the phenotype and the profile of the associated hormonal resistance allow a first approximation. Therefore, it is essential to rule out a calcium disorder in all patients with convulsive syndrome or calcifications in the basal ganglia using central nervous system imaging.

Conflicts of interest

None stated by the authors.

Funding

None stated by the authors.

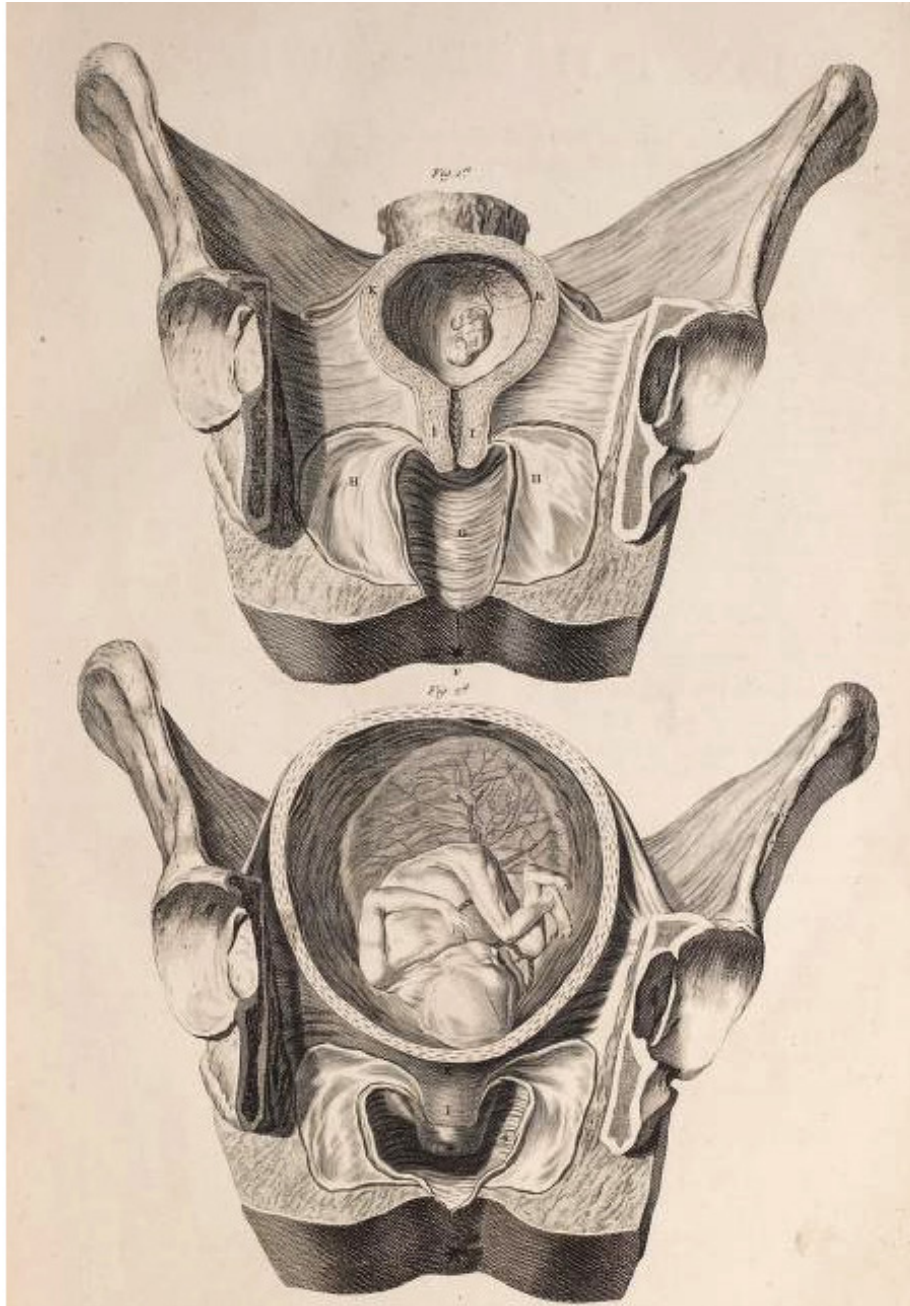
Acknowledgements

None stated by the authors.

References

1. Clarke BL, Brown EM, Collins MT, Jüppner H, Lakatos P, Levine MA, *et al.* Epidemiology and Diagnosis of Hypoparathyroidism. *J Clin Endocrinol Metab.* 2016;101(6):2284-99. <http://doi.org/cq55>.
2. Cooper MS, Gittoes NJ. Diagnosis and management of hypocalcaemia. *BMJ.* 2008;336(7656):1298-302. <http://doi.org/cs8793>.
3. Tafaj O, Jüppner H. Pseudohypoparathyroidism: one gene, several syndromes. *J Endocrinol Invest.* 2017;40(4):347-56. <http://doi.org/f93pqf>.
4. Maeda SS, Fortes EM, Oliveira UM, Borba VC, Lazaretti-Castro M. Hypoparathyroidism and pseudohypoparathyroidism. *Arq Bras Endocrinol Metabol.* 2006;50(4):664-73. <http://doi.org/djvqjz>.
5. Reis MT, Cattani A, Mendonca BB, Correa PH, Martin RM. A novel GNAS mutation in an infant boy with pseudohypoparathyroidism type 1a and normal serum calcium and phosphate levels. *Arq Bras Endocrinol Metabol.* 2010;54(8):728-31. <http://doi.org/drsscw>.
6. Fischer JA, Bourne HR, Dambacher MA, Tschopp F, De Meyer R, Devogelaer JP, *et al.* Pseudohypoparathyroidism: inheritance and expression of deficient receptor-cyclase coupling protein activity. *Clin Endocrinol (Oxf).* 1983;19(6):747-54. <http://doi.org/d4n599>.
7. Farfel Z, Brothers VM, Brickman AS, Conte F, Neer R, Bourne HR. Pseudohypoparathyroidism: inheritance of deficient receptor-cyclase coupling activity. *Proc Natl Acad Sci U S A.* 1981;78(5):3098-102. <http://doi.org/cf28c3>.
8. Aida M, Hurukawa Y, Miura K, Mihara A, Kato K. Responsiveness of urinary cyclic AMP and phosphate to parathyroid extract in patients with parathyroid disorders. *Tohoku J Exp Med.* 1975;115(4):319-25. <http://doi.org/d6qw55>.
9. Shoemaker AH, Jüppner H. Nonclassic features of pseudohypoparathyroidism type 1A. *Curr Opin Endocrinol Diabetes Obes.* 2017;24(1):33-8. <http://doi.org/f9kfwf>.
10. Velez I, Bond M, Ellen S, Ede-Nichols D, Larumbe J, Oramas V, *et al.* Hereditary osteodystrophy with multiple hormone resistance--a case report. *J Clin Pediatr Dent.* 2009;34(1):67-9. <http://doi.org/cq58>.
11. Cartier L, Passig C, Gormaz A, López J. Cambios neuropsicológicos y neurofisiológicos en la enfermedad de Fahr: Report of three sisters. *Rev Med Chil.* 2002;130(12):1383-90. <http://doi.org/ccgt67>.
12. Manyam BV. What is and what is not 'Fahr's disease'. *Parkinsonism Relat Disord.* 2005;11(2):73-80. <http://doi.org/bdf72>.

13. Piñol-Ripoll G, Mauri-Llerda JA, de la Puerta Martínez-Miró I, Pérez-Lázaro C, Beltrán-Marín I, López Del Val LJ, *et al*. Diagnóstico diferencial de las calcificaciones intracraneales. *Rev Neurol*. 2005;41(3):151-5.
14. Iglesias-Bolaños P, Gutiérrez-Medina S, Bartolomé-Hernández L. Late diagnosis of 1b pseudohypoparathyroidism. *Med Clin (Barc)*. 2017;149(11):508-9. <http://doi.org/cq59>.
15. Bosworth M, Mouw D, Skolnik DC, Hoekzema G. Clinical inquiries: what is the best workup for hypocalcemia? *J Fam Pract*. 2008;57(10):677-9.
16. Kuzel AR, Lodhi MU, Rahim M. Classic and Non-Classic Features in Pseudohypoparathyroidism: Case Study and Brief Literature Review. *Cureus*. 2017;9(11):e1878. <http://doi.org/cq6b>.
17. Mantovani G. Clinical Review: Pseudohypoparathyroidism: diagnosis and treatment. *J Clin Endocrinol Metab*. 2011;96(10):3020-30. <http://doi.org/bbcbzv>.
18. Ucrós-Cuellar A, Gómez J. A propósito de 3 hermanos con trastornos morfológicos sin tetania e hipo-reactividad a la Parathormona ¿Una nueva entidad clínica? *Rev Soc Colomb Endocrinol*. 1957;1:181-96.
19. Bernal E, Hernández C, Reyes B. Hipoparatiroidismo posttiroidectomía, hipoparatiroidismo primario y pseudohipoparatiroidismo. Informe de tres casos. *Acta Médica Colombiana*. 1979;4(4):187-92.
20. Lopes MP, Kliemann BS, Bini IB, Kulchetscki R, Borsani V, Savi L, *et al*. Hypoparathyroidism and pseudohypoparathyroidism: etiology, laboratory features and complications. *Arch Endocrinol Metab*. 2016;60(6):532-6. <http://doi.org/cq6d>.
21. Underbjerg L, Sikjaer T, Mosekilde L, Rejnmark L. Pseudohypoparathyroidism - epidemiology, mortality and risk of complications. *Clin Endocrinol (Oxf)*. 2016;84(6):904-11. <http://doi.org/cq6f>.



WILLIAM SMELLIE, M.D. (1754)

*"A Sett of Anatomical Tables with explanations and an
abridgement of the Practice of Midwifery"*