



Autosomal chronic granulomatous disease: case report and mutation analysis of two Brazilian siblings

**Carolina Prando-Andrade,¹ Piedad Agudelo-Florez,²
Juan A. Lopez,³ Maria Aparecida de Souza Paiva,⁴ Beatriz T. Costa-Carvalho,⁵
Antonio Condino-Neto⁶**

Abstract

Objective: To report the case of two siblings with chronic granulomatous disease. Chronic granulomatous disease is a primary immunodeficiency disorder characterized by abnormal microbicidal activity. Mutations in the p47-phox gene (NCF-1) are present in about 30% of the patients with chronic granulomatous disease; this group presents a better prognosis and later onset of recurrent infections as compared with the X-linked variant, present in about 56% of patients.

Description: Case 1 is a female presenting repeat infections since age 10, starting with impetigo followed by severe pneumonia six months later. The severity of the lung infection associated with liver abscess and the patient's resistance to treatment prompted laboratory investigation for immunodeficiency. The results of the nitroblue tetrazolium and superoxide release tests were consistent with a diagnosis of chronic granulomatous disease. The parents and siblings were assessed, revealing the presence of granulomatous disease in a brother (Case 2). He also presented repeat infections with impetigo at age 10, followed by pneumonia six months later, however in a non severe form. Single-strand conformational polymorphism analysis detected abnormal electrophoretic mobility of exon 2 of the NCF-1 gene. Sequence DNA analysis revealed a dinucleotide GT deletion in exon 2.

Comments: It is important to evaluate the relatives of chronic granulomatous disease patients, even in the absence of typical clinical signs. Defining the mutation and its correlation with phenotype is important to provide appropriate genetic counseling and clinical prognosis.

J Pediatr (Rio J). 2004;80(5):425-8: Chronic granulomatous disease, immunodeficiency, NADPH oxidase, p47-phox.

1. M.Sc.; Doctoral student in Pharmacology, School of Medicine, Universidade Estadual de Campinas (UNICAMP), Campinas, SP, Brazil.
2. Ph.D., School of Medicine, Universidade Estadual de Campinas (UNICAMP), Campinas, SP, Brazil.
3. Ph.D., School of Medicine, Universidade Estadual de Campinas (UNICAMP), Campinas, SP, Brazil.
4. Chief of the Division of Pediatric Pneumology, Hospital dos Servidores do Estado do Rio de Janeiro, Rio de Janeiro, RJ, Brazil.
5. Ph.D. Associate professor, Department of Pediatrics, Escola Paulista de Medicina, Universidade Federal de São Paulo (UNIFESP), São Paulo, SP, Brazil.
6. Associate professor, Department of Pediatrics, School of Medicine, Universidade Estadual de Campinas (UNICAMP), Campinas, SP, Brazil.

Financial support: Fundação de Amparo à Pesquisa do Estado de São Paulo (FAPESP 01/14365-3 and 02/05880-4), Conselho Nacional de Desenvolvimento Científico e Tecnológico (CNPq 302685/02, 470413/03) and The United States National Institutes of Health Fogarty International Center (1RO3TW00883-01).

Manuscript received Dec 18 2003, accepted for publication May 12 2004.

Suggested citation: Prando-Andrade C, Agudelo-Florez P, Lopez JA, Paiva MAS, Costa-Carvalho BT, Condino-Neto A. Autosomal chronic granulomatous disease: case report and mutation analysis of two Brazilian siblings. *J Pediatr (Rio J)*. 2004;80:425-8.

Introduction

Chronic granulomatous disease (CGD) is a syndrome characterized by genetic abnormalities which result in defective production of oxygen reactive species, interfering in the capacity of leukocytes to destroy microorganisms.¹

The incidence of CGD is approximately 1 in 250,000 live births.²

A genetic abnormality at the gp91-phox, p22-phox, p47-phox or p67-phox proteins that are part of the NADPH oxidase system can result in an expression and/or function failure of this electron transport system, leading to the CGD phenotype.³

The most common form of CGD is caused by a defect in gp91-phox, which has X-linked inheritance (X-CGD, 56%), followed by the autosomal recessive forms resulting from an alteration to p47-phox (A47-CGD, 30%), p22-phox (A22-CGD, 5 to 7%) and p67-phox (A67-CGD, 5 to 7%).²

Clinically CGD is characterized by repeated catalase-positive microorganism infections, primarily *Staphylococcus aureus*, gram-negative bacteria and *Aspergillus*, in addition to intracellular microorganisms, such as *Pneumocystis carinii* and *Mycobacterium spp*, which frequently affect the skin, lungs, liver, spleen, lymph nodes and bones.² Inflammatory granulomas can form in the gastrointestinal tract and urinary system, causing obstructive symptoms in the esophagus, stomach or duodenum,⁴ in addition to manifestations similar to intestinal inflammatory disease.⁵

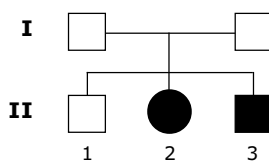
Patients with X-linked heredity present earlier manifestations, during the first year of life, and diagnosis is generally made before 2 years.^{2,6} Additionally, infections tend to be more serious and the number of hospitalizations is greater than for patients with recessive autosomal heredity.^{2,6}

According to the Pan American Primary Immunodeficiency Study Group (PAGID - *Grupo Pan-Americano de Estudo em Imunodeficiências Primárias*), CGD diagnosis is made for males or females based on the nitroblue tetrazolium (NBT) test or the presence of altered phagocyte respiratory burst (less than 5% of the controls) and who present: gp91-phox, p22-phox, p47-phox or p67-phox mutations or absent mRNA observed by Northern blot analysis for one of the genes listed or mother, cousins, uncles or nephews with abnormal NBT results or respiratory burst.⁷

The NBT test on slides is an extremely useful method for CGD diagnosis, and also allows carriers of the defect (mothers, sisters) in X-CDG cases.⁸

This study presents a clinical, biochemical and molecular analysis of two siblings with autosomal recessive CGD due to a p47-phox defect.

Description of the cases



Case 1 (II.2 - Adr.O.M., female)

The second daughter of non-consanguineous parents. Received complete basic immunization with no adverse

reactions and presented adequate pondero-statural and neuropsychomotor development.

In June 1992, at 10 years of age, presented with pneumonia treated over two fifteen-day periods with ampicillin, followed by 45 days on a triple regime for tuberculosis, without improvement. She was then given cephalothin and chloramphenicol, progressing with a discrete clinical and radiological improvement. The pulmonary biopsy performed at this stage of the treatment found non-specific inflammation with lymphohistiocytic infiltration and the presence of multi-nucleus giant-cell granulocytes and fibrosis encirclement; the culture taken from this material was negative for fungi and bacteria. Broncho-alveolar lavage cultures were positive for *Candida sp* and *Streptococcus pneumoniae*.

The patient progressed with chronic lung disease and required renewed hospitalization in February, to treat pneumonia and liver abscess, and April 1993. It was at this point that the diagnosis of CGD was established by NBT reduction in granulocytes stimulated with phorbol myristate acetate (PMA) (1 µg/ml) of < 5% that of the control and the patient's mother. Similarly, superoxide anion production in response to PMA stimulus (30nM) in the presence of cytochrome C (80 µM) was very low in comparison with the healthy control and the mother (Table 1).

She was discharged from her last hospitalization on ciprofloxacin and human recombinant gamma interferon exhibiting a moderate level of control over the lung infections.

The following year, the gamma interferon was withdrawn and since then she has been using sulfamethoxazole and trimethoprim irregularly. She progresses with significant improvements in the lung condition with normal pulmonary function. Over the 9-year follow-up period, she presented bartholinitis (1999) and a case of single pneumonia (2003), both treated with success in outpatients.

Case 2 (II.3 - Adm.O.M., male)

In common with his sister, the patient received full basic immunization with no adverse reactions and always exhibited adequate pondero-statural and neuropsychomotor development.

Presented three episodes of impetigo affecting the axillary region bilaterally and the lower limbs, in 2000. In January of 2001, presented pneumonia which was treated for 10 days with sulfamethoxazole and trimethoprim.

Table 1 - Superoxide anion level of patients with CGD

| Patient | Spo PMN* | PMN PMA [†] | Spo MONO ‡ | MONO PMA [§] |
|----------|----------|----------------------|------------|-----------------------|
| Adr.O.M. | 1.0 | 1.03 | -1.33 | 0.37 |
| Ade.O.M. | -0.01 | 1.94 | 0.37 | 0.37 |
| Control | 5.12 | 13.04 | 1.75 | 12.94 |

* Spontaneous release of superoxide anion by polymorphonuclear cells.

[†] Release of superoxide anion by polymorphonuclear cells stimulated with phorbol myristate acetate (PMA).

[‡] Spontaneous release of superoxide anion by mononuclear cells.

[§] Release of superoxide anion by mononuclear cells stimulated with PMA.

Between August and December of 2001, presented two further episodes of impetigo, responding adequately to antibiotic treatment.

The elder brother of these two patients and also their mother and father are asymptomatic.

Disease presentation in both sexes was suggestive of CGD with recessive autosomal heredity, i.e. abnormalities in protein p47, p67 or p22-phox. Of all these CGD variants, that which exhibits the most favorable clinical outcome, as exhibited by the patients described here, is A47-CGD. In order to determine whether this was indeed a case of abnormal NADPH oxidase system behavior, a single-strand conformational polymorphism (SSCP) analysis was initially performed for the p47-phox chain. This method allows mutations to be detected by means of a three-dimensional view of the DNA structure. In the knowledge that the great majority of patients with A47-CGD present a homozygous deletion of GT nucleotides at the start of exon 2 of the NCF-1 gene (*GenBank* access number: NM 000265), polymerase chain reaction (PCR) was performed with the oligonucleotide 48F-451R. In order to do this we used genomic DNA (gDNA) in PCR, which is subjected to electrophoresis under denaturing conditions. A migratory pattern was observed in both patients that was distinct from the patterns observed in two healthy individuals (Figure 1).

This specific DNA region was then sequenced using a commercially available kit (DNA sequencing Kit, Big Dye Terminator Cycle Sequencing Ready Reaction for ABI 377 PE/Applied Biosystems), as previously published, confirming that both patients exhibited the GT (Δ GT) deletion at the start of exon 2 (Figure 2).

Comments

Abnormal NADPH oxidase activity, characteristic of CGD, results in an important deficiency that involves the initial stage of the defense against infections. Since there is a great deal of contact between external agents and the skin and respiratory and gastrointestinal mucosa, the organisms natural barriers, these areas, together with adjoining tissues, are the primary targets of microbial invasion and are frequently the site of infectious processes in CGD patients.^{2,9} Both patients in this study exhibited late-onset infections, and only Adr.O.M. presented severe infection. Other than skin and lung infections and liver abscess, they did not present other frequent CGD-linked infectious conditions, such as abscesses of soft tissues, suppurating adenitis and osteomyelitis.

Pulmonary infections constitute the most common form of invasive infection in CGD,² and pulmonary involvement is associated with a significant increase in morbidity and mortality, since repeated pneumonia can progress to bronchiectasis and pulmonary fibrosis.

While the topography of the infectious processes was suggestive of a phagocyte-related immunodeficiency, the favorable clinical progress contrasts with descriptions of CGD patients.¹⁰ Recently, a sample of 368 patients described by Winkelstein *et al.* demonstrated earlier onset of symptoms

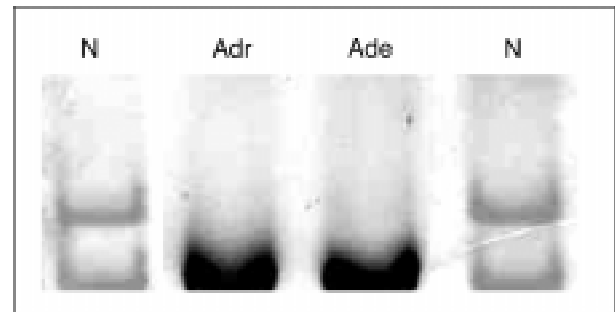


Figure 1 - Single-strand conformational polymorphism of patients with CGD: migratory pattern of exon 2 of the NCF-1 gene. Note the abnormal migratory pattern in the patients (Adr, Ade) if compared to normal subjects (N). In the autosomal recessive genetic pattern, the mutation presents a homozygous form, and, therefore, in the electrophoretic mobility, both DNA bands overlay each other (Adr, Ade)

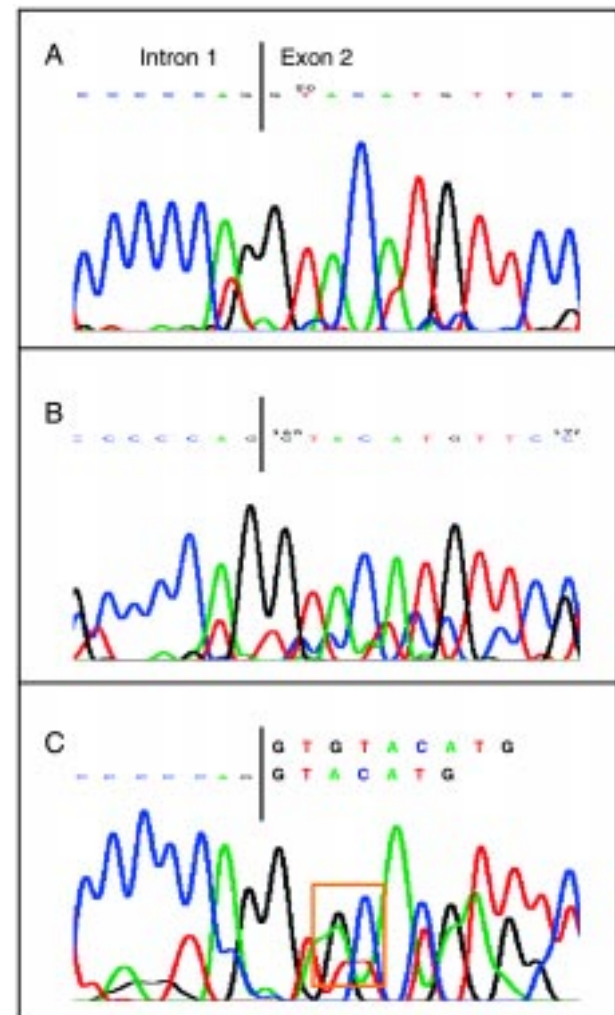


Figure 2 - Genomic DNA sequencing of patients with CGD and control: analysis of the sequence of the exon 2 of the NCF-1 gene. **A:** Patient Adr. Note a deletion of the GT nucleotide (Δ GT) at the start of the exon 2. **B:** Patient Ade. Note the same Δ GT mutation in the base of the exon 2. **C:** Control, note the double sequence of the NCF-1 gene (upper sequence) with the presence of the pseudogene (lower sequence), and the G bases (black) and T bases (red) are highlighted, which are not present in Figures 2A and 2B

and greater mortality rate among patients with X-linked CGD ($p < 0.02$).² Furthermore, a greater prevalence of inflammatory manifestations was observed, causing gastric and urinary obstructions, and also of certain types of infection (perirectal abscesses, suppurating adenitis and septicemia) among the patients with X-CDG.²

According to some authors, the more favorable outcomes observed with A47-CGD may be attributable to a residual level of hydrogen peroxide and superoxide production by neutrophils deficient in p47-phox.¹¹ We, however, observed extremely low levels in the patients described here, similar to the levels seen in Brazilian patients with X-CGD.¹²

Another important characteristic of A47-CGD is the fact that the same NCF-1 mutation is found in different families, in contrast with X-CGD for which 300 mutations have been described, 200 of which were exclusive to each family.¹³ Among the 82 patients with p47-phox abnormalities who had been studied by the year 2000, 74 presented the same mutation, a homozygous deletion of the GT nucleotide, corresponding to the first four bases of the second exon of the NCF-1 gene. The remaining patients were either heterozygotes for the GT deletion ($n = 6$) or presented some other mutation in association with the GT deletion ($n = 2$).¹⁴ The elevated frequency of the GT deletion at the start of exon 2 of the NCF-1 gene in unrelated patients, impacting on p47-phox, is explained by the existence of a highly homologous pseudogene, which, by means of meiotic recombination phenomena which result in the normal gene being eliminated or corrupted.¹⁵ Two new mutations to the NCF-1 gene were identified recently: one is a G579A homozygous mutation, forming a stop codon, with the patient's parents being heterozygotes for the mutation, and the second case is a heterozygous G579A mutation.¹⁶

Studies that describe the interrelated clinical and molecular aspects of CGD are important to establish prognosis, adequate genetic counseling and possible future therapy.

Testing for CGD in relatives of patients who have been diagnosed should be considered even when these relatives do not exhibit characteristic clinical signs and symptoms. It is possible that the autosomal recessive forms of CGD may occur with greater frequency than is currently observed, if they were to be researched more often and in greater depth.

References

1. Curnutte JT. Chronic granulomatous disease: the solving of a clinical riddle at the molecular level. *Clin Immunol Immunopathol*. 1993;67(3 Pt 2):S2-15.

2. Winkelstein JA, Marino MC, Johnston RB Jr., Boyle J, Curnutte J, Gallin JI, et al. Chronic granulomatous disease. Report on a national registry of 368 patients. *Medicine (Baltimore)*. 2000;79(3):155-69.
3. Leusen JH, Verhoeven AJ, Roos D. Interactions between the components of the human NADPH oxidase: intrigues in the phox family. *J Lab Clin Med*. 1996;128:461-76.
4. Renner WR, Johnson JF, Lichtenstein JE, Kirks DR. Esophageal inflammation and stricture: complication of chronic granulomatous disease of childhood. *Radiology*. 1991;178: 189-91.
5. Al-Binali AM, Scott B, Al-Garni A, Montgomery M, Robertson M. Granulomatous pulmonary disease in a child: an unusual presentation of Crohn's disease. *Pediatr Pulmonol*. 2003;36: 76-80.
6. Liese J, Kloos S, Jendrosseck V, Petropoulou T, Wintergerst U, Notheis G, et al. Long-term follow-up and outcome of 39 patients with chronic granulomatous disease. *J Pediatr*. 2000;137:687-93.
7. Conley ME. Diagnostic guidelines—An International Consensus document. *Clin Immunol*. 1999;93:189.
8. Ochs H, Igo RP. The NBT slide test: a simple screening method for detecting chronic granulomatous disease and female carriers. *J Pediatr*. 1973;83:77-82.
9. Segal BH, Leto TL, Gallin JI, Malech HL, Holland SM. Genetic, biochemical, and clinical features of chronic granulomatous disease. *Medicine (Baltimore)*. 2000;79:170-200.
10. Bridges RA, Berendes H, Good RA. A fatal granulomatous disease of childhood. The clinical, pathological and laboratory features of a new syndrome. *Am J Dis Child*. 1959;97:387-408.
11. Cross AR, Yarchover JL, Curnutte JT. The superoxide-generating system of human neutrophils possesses a novel diaphorase activity. Evidence for distinct regulation of electron flow within NADPH oxidase by p67-phox and p47-phox. *J Biol Chem*. 1994;269:21448-54.
12. Andrade CCP. Aspectos clínicos de pacientes sob suspeita de imunodeficiência fagocitária [dissertação]. Campinas: Universidade Estadual de Campinas; 2003.
13. Heyworth PG, Curnutte JT, Rae J, Noack D, Roos D, van Koppen E, et al. Hematologically important mutations: X-linked chronic granulomatous disease (second update). *Blood Cells Mol Dis*. 2001;27:16-26.
14. Roesler J, Curnutte JT, Rae J, Barrett D, Patino P, Chanock SJ, et al. Recombination events between the p47-phox gene and its highly homologous pseudogenes are the main cause of autosomal recessive chronic granulomatous disease. *Blood*. 2000;95: 2150-6.
15. Vazquez N, Lehrnbecher T, Chen R, Christensen BL, Gallin JI, Malech H, et al. Mutational analysis of patients with p47-phox-deficient chronic granulomatous disease: The significance of recombination events between the p47-phox gene (NCF1) and its highly homologous pseudogenes. *Exp Hematol*. 2001;29: 234-43.
16. de Boer M, Singh V, Dekker J, Di Rocco M, Goldblatt D, Roos D. Prenatal diagnosis in two families with autosomal, p47(phox)-deficient chronic granulomatous disease due to a novel point mutation in NCF1. *Prenat Diagn*. 2002;22:235-40.

Corresponding author:

Antonio Condino-Neto
 Centro de Investigação em Pediatria,
 Faculdade de Ciências Médicas, UNICAMP
 Cx. Postal 6111
 CEP 13081-970 - Campinas, SP
 Brazil
 Phone: +55 (19) 3788.8988
 Fax: +55 (19) 3289.8638
 E-mail: condino@lexxa.com.br